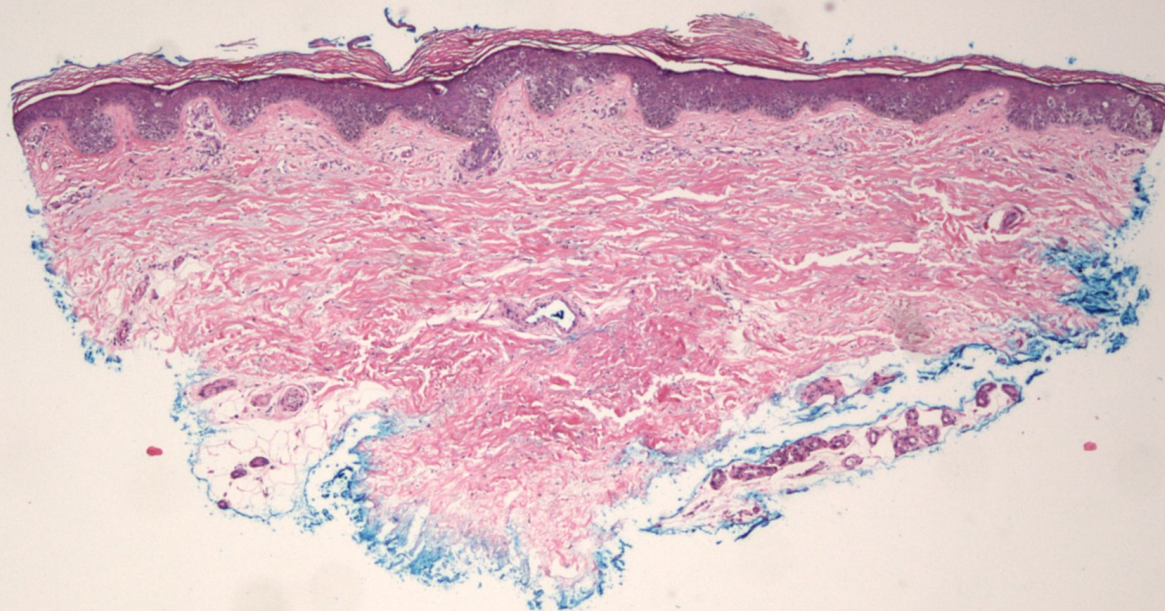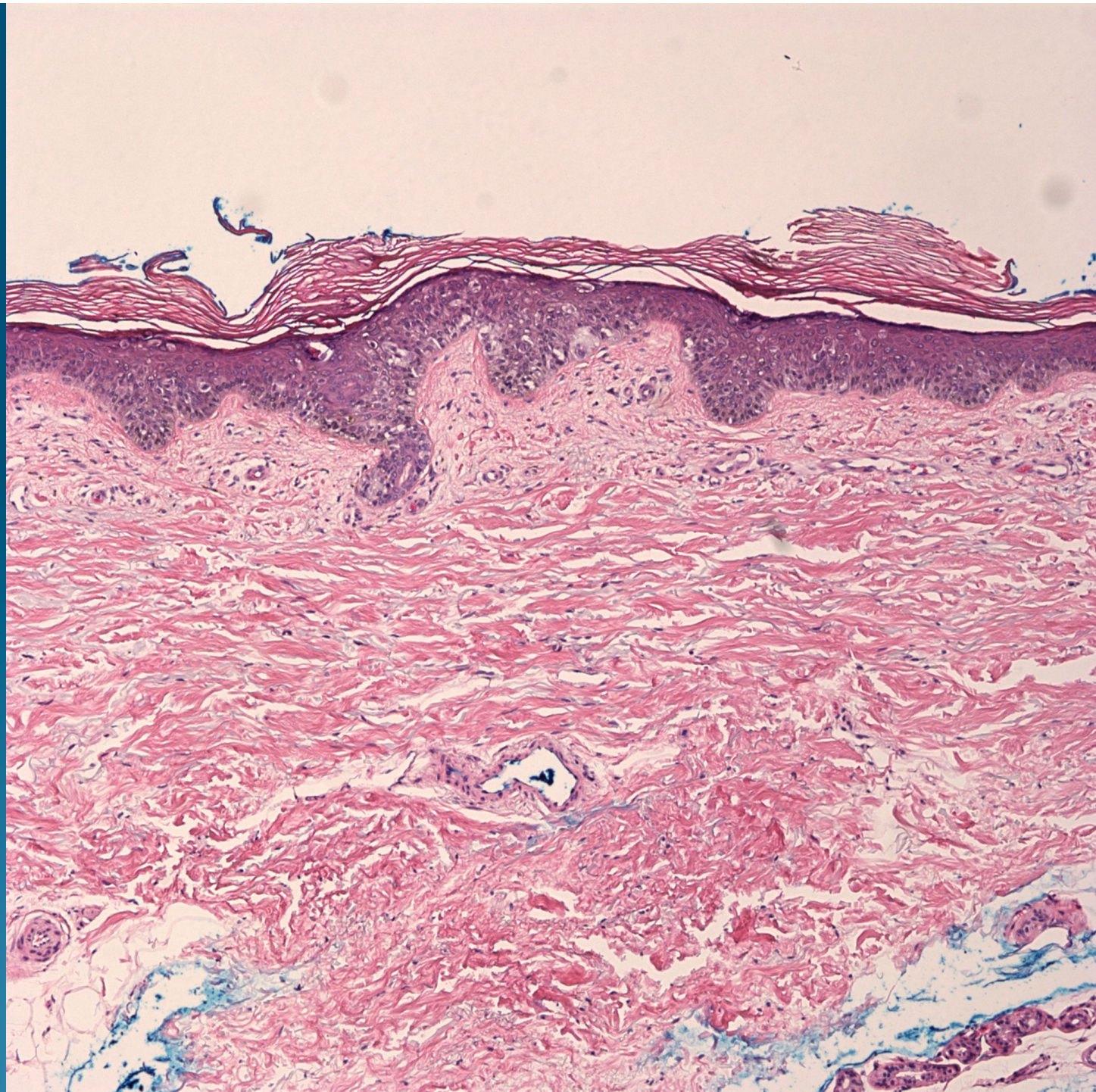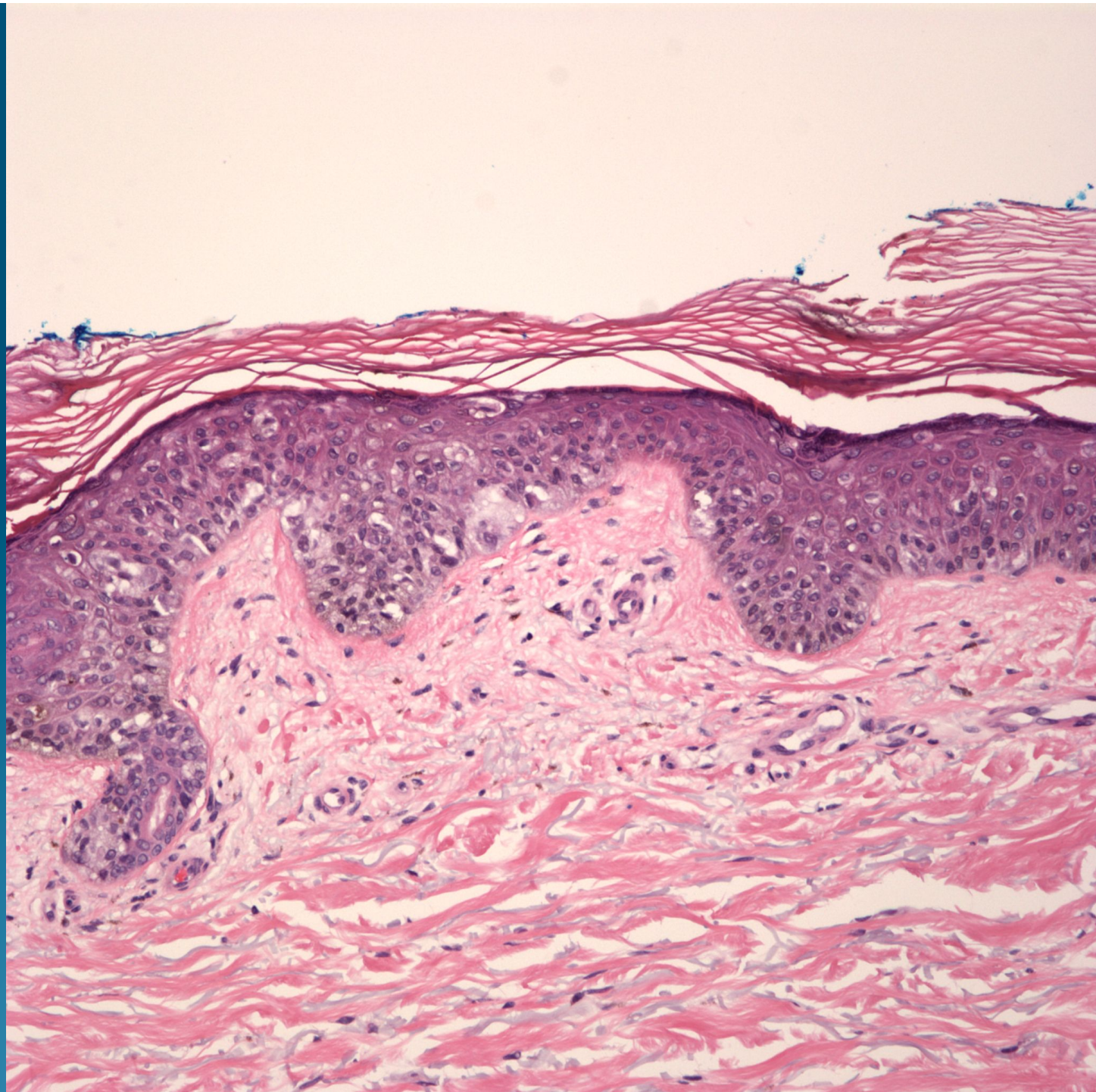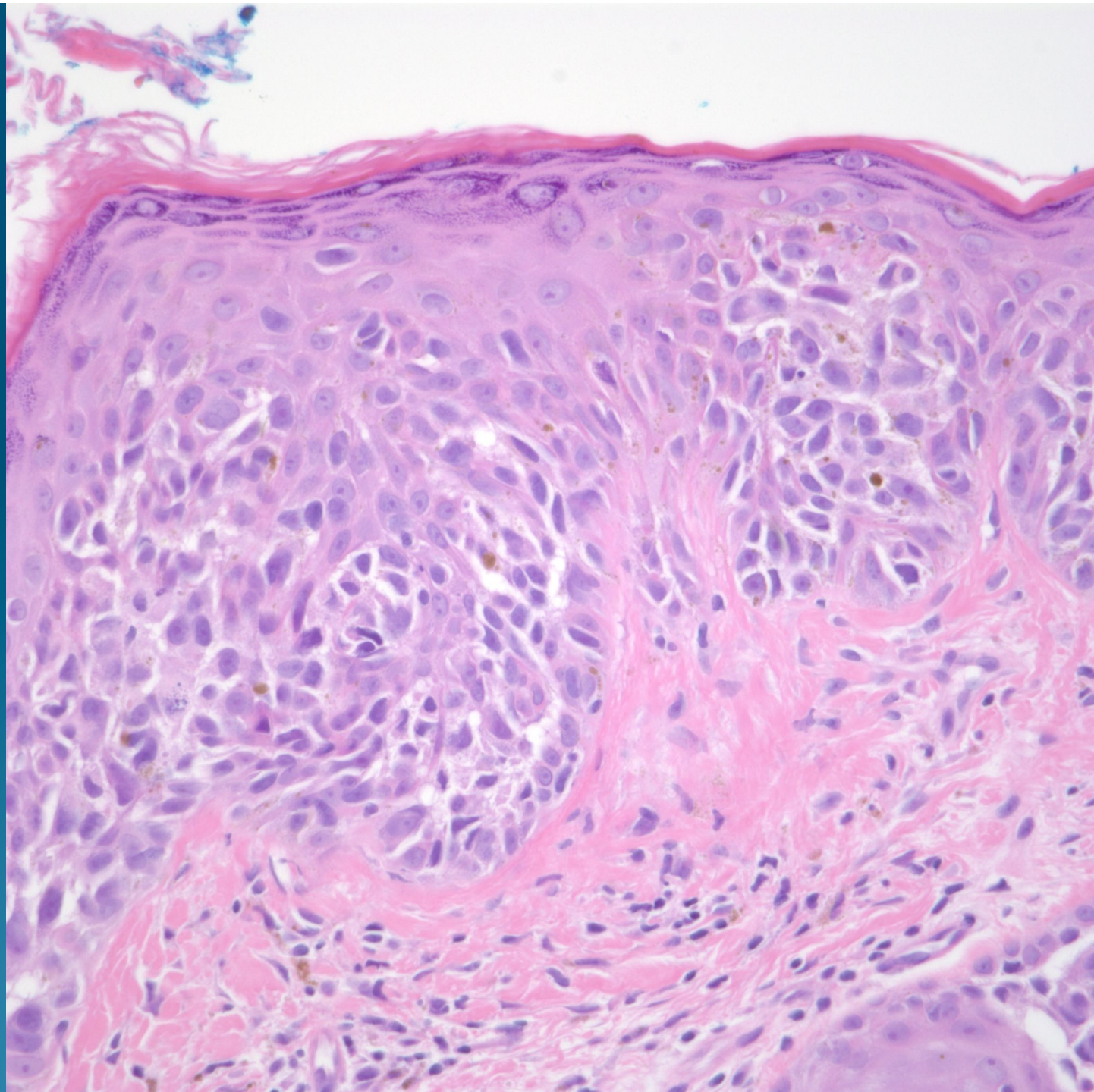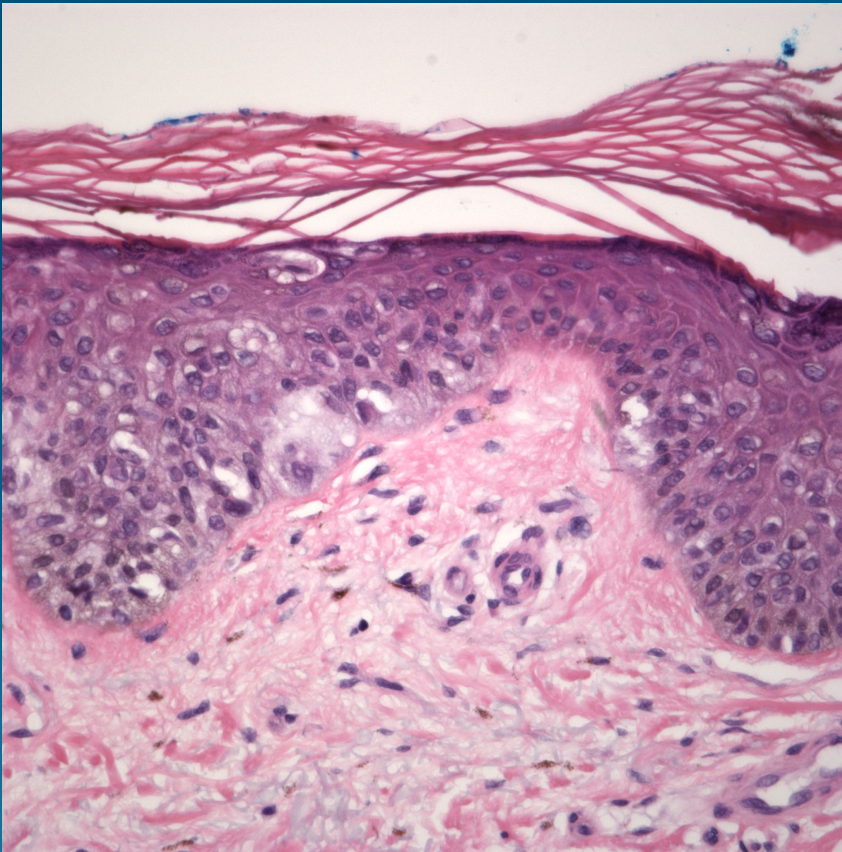


What is the best diagnosis?

- A. Hidroacanthoma simplex
- B. Superficial basal cell carcinoma
- C. Actinic keratosis
- D. Mycosis fungoides
- E. Malignant melanoma in situ

Malignant Melanoma in Situ, Superficial Spreading Type

Pearls



- Haphazard proliferation of atypical melanocytes (Pagetoid spread)
- Variable melanin pigmentation
- Usually solar elastosis
- May need to confirm with IHC to differentiate from SCCIS and Paget's.